



ECRE

Al Mr	Oj	Bli Or,	Ra
.5-1	.5-1.5	1-2	0,1,2
Not L4s	Cusp/Groove	Not L4s	
Max Grooves		Not DL7s	
Man Cusps			

CEPH NORMS

SNA	82 +/- 2
SNB	80 +/- 2
ANB	2 +/- 2
SN-MP(CG)	32 +/- 4
FMA	25 +/- 4

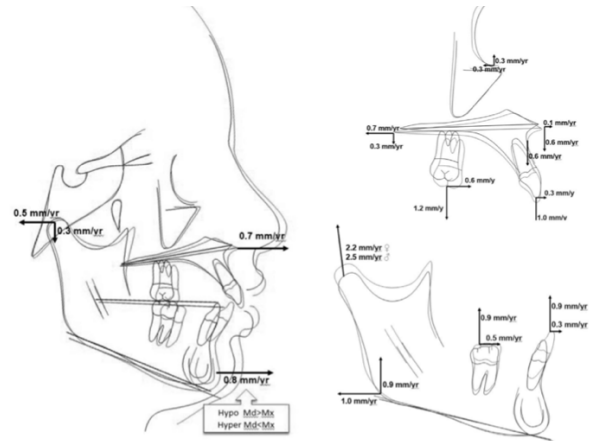
U1-SN	103 +/- 5
U1-PP	110 +/- 5
U1-NA	4 +/- 2

IMPA	90 +/- 5
L1-NA	4 +/- 2

RACIAL/ETHNIC VARIATIONS

Notes for any personal memory jogging about treatment norms

BUSCHANG/ROLDAN/TADLOCK GROWTH #S

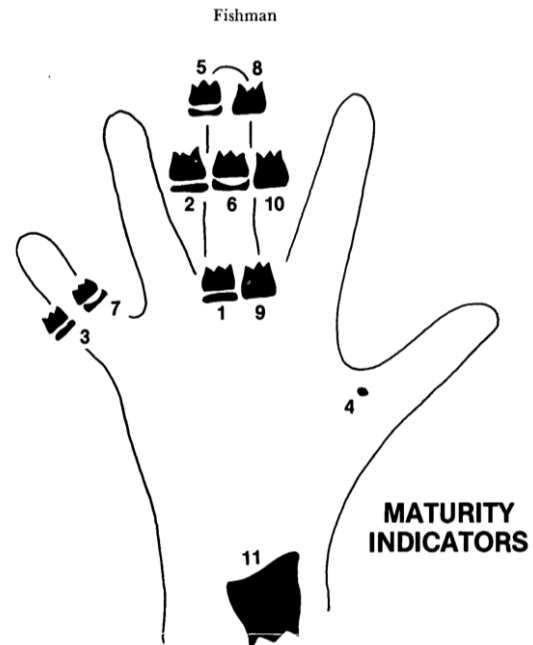


“GOOD” vs. “BAD” GROWERS

Condyle	SN-MP
Gonial Angle	Symphysis
Antegonial Notch	PFH / AFH

SMI

Widen, Sesamoid, Cap, Fuse



CVMS

- 1,2 Pre-pubertal – 2 get ready w/in 1 yr
- 3,4 Circum-pubertal – 4 Rhomboid
- 5,6 Post-pubertal – 5 Square



	ANTR-POSTR	TRANSVERSE	VERTICAL
Skeletal	<p>SNA, SNB, ANB Skeletal Class Chin Position</p> <p>GROWTH: CS, SMI, Horizontal v. Vertical Grow, Menarche</p>	<p>U6-U6/L6-L6 Asymmetry Postr Skeletal Crossbite</p>	<p>SN-MP / FMA FaceType–Brachy,Meso,Dolicho Divergence Cranial Base PFH/AFH VME Gonial Angle/Notch/Y-Axis Skel Open Bite Palatal Plane Tip Ramus Height</p>
Soft Tissue	<p>Profile – Nose/Tip – NLA Lip Thickness, ML Fold Chin Projection Chin-Throat Length/Angle</p> <p>Weak/Strong Face Muscles Midface Deficient/Malar</p>	<p>Symmetry – Nose/Chin Buccal Corridors Facial 5ths Lip Commissure Smile Consonance Esthetics Alar Base</p>	<p>Facial 3rds Lower 2/3 of the Lower 1/3 Lip Competence Philtrum / Mentalis Strain U1 – Rest mm / Animation mm Gingival Display Submental Fat VME SoftTissue (short lip)</p>
Dental	<p>Molar / Canine – L/R Division / Subdivisions Overjet - Antr Crossbites U1-SN / U1-PP / U1-NA U1-L1 L1-MP / L1-NA Bimax Protrusion</p>	<p>Postr Crossbite Curve of Wilson/Monson Symmetry – Midlines Cant Width L3-L3 Arches – shape, symmetry, crowding (ALD) Bolton Tooth Size Discrep</p>	<p>Overbite / % Impinging Bite Antr Open Bite Postr Open Bite Supra/Infraeruption U1/L1 Curve of Spee U6/L6 Vertical Eruption</p>
Other	<p>TMJ, Deviations CR-CO Shift Previous Ortho Pathology Multidisciplinary Tongue? Habits? Bruxism?</p>	<p>Primary teeth Ectopic/Impacted/Missing Ankylosed/Root Resorption Diastemata Rotations / Marg Ridges Teeth Shape Stain / Decalcification Embrasures / Connectors</p>	<p>Oral Hygiene Tissue BioType Perio Concerns: Frenum Probing / PSR Recession Black Triangles</p>